

A decorative graphic consisting of a thin yellow circle. A thick, horizontal bar with a gradient from olive green to light yellow is positioned across the middle of the circle. On the left side of the bar, a black bracket-like shape is attached to the circle. On the right side, a yellow bracket-like shape is attached to the circle.

Head, Neck, and Trunk Injury

www.fisiokinesiterapia.biz

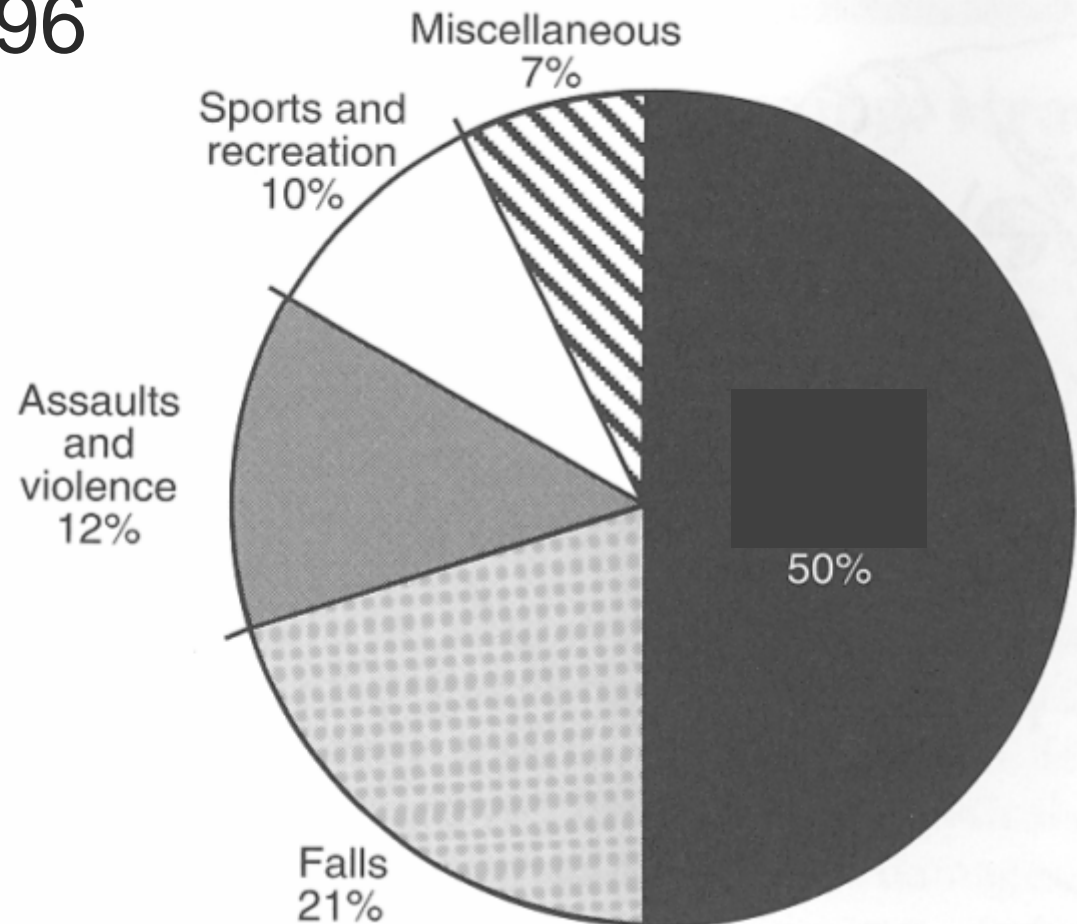
[Overview]

- Head
 - Brain

- Neck/Trunk
 - Spine

[Causes of Head Injury]

- McGehee 1996



[Unique mechanics]

- Skull: stiff, slightly compressible container
- Brain: compliant tissue
 - Most important structure
- Intracranial tissues

Classifications

- Focal injury
 - Tissue damage restricted to a limited area
- Diffuse injury
 - Damages over a large region of neural tissue
- Closed injury
 - No exposure to external environment
- Penetrating injury
 - Direct penetration of the skull and its neurovascular contents

[Motion]

■ Acceleration vs. Deceleration

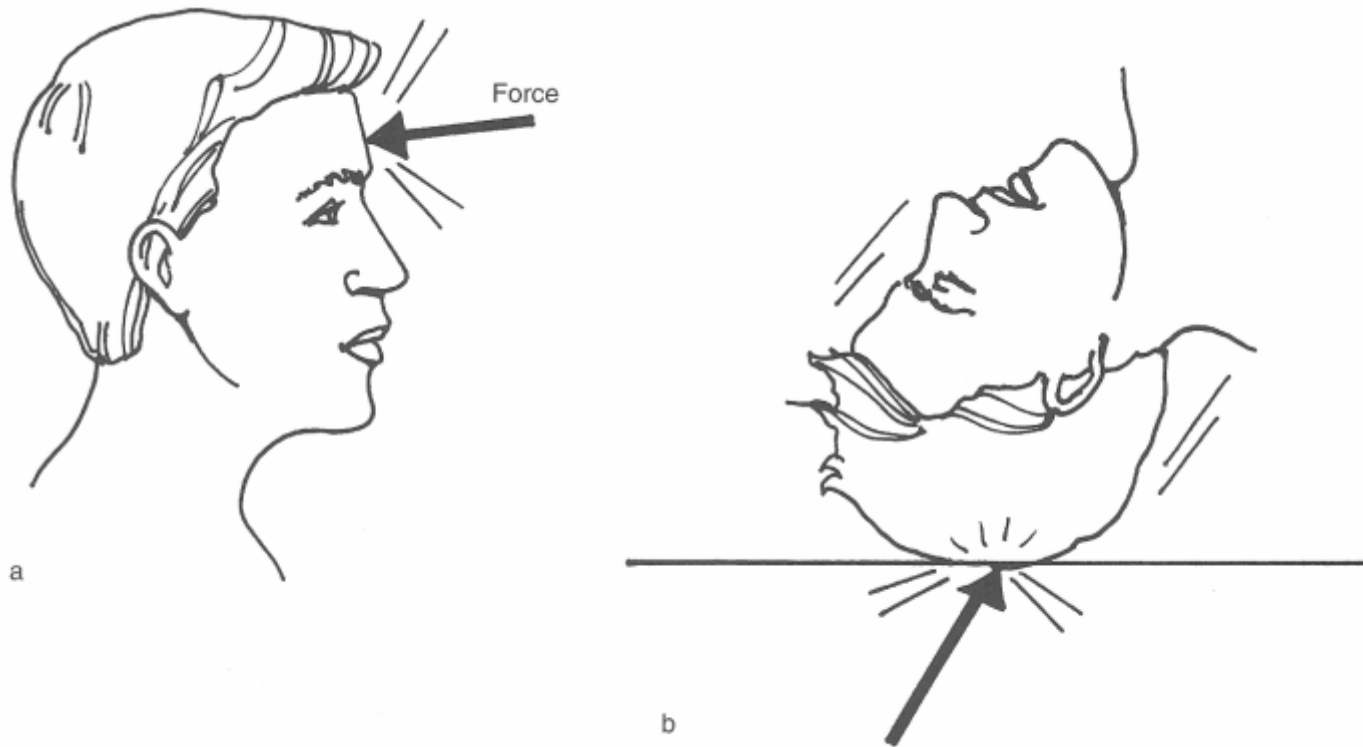


Figure 8.4 (a) Force applied to a stationary head. (b) Impact force created by contact of a moving head with an unyielding surface.

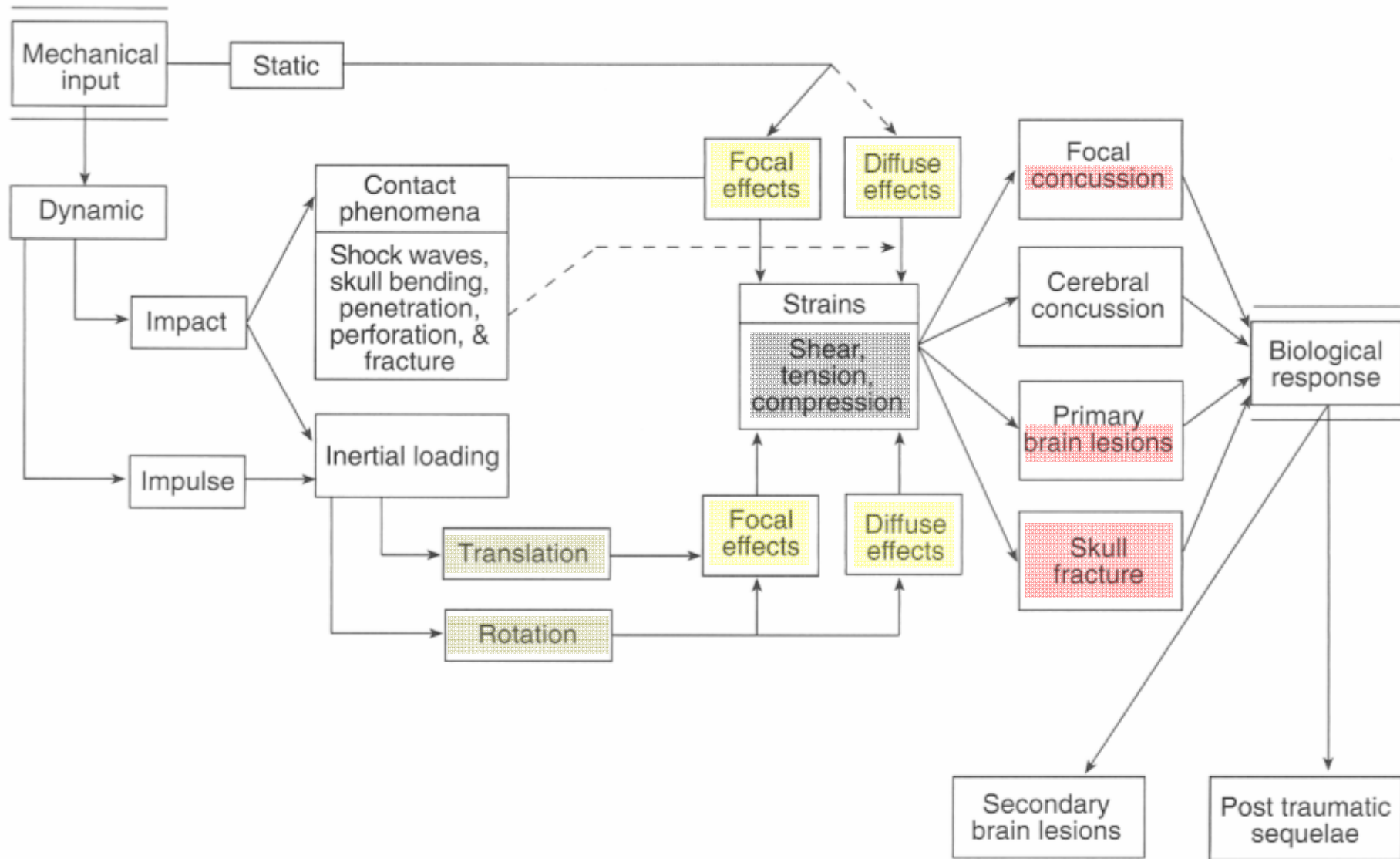


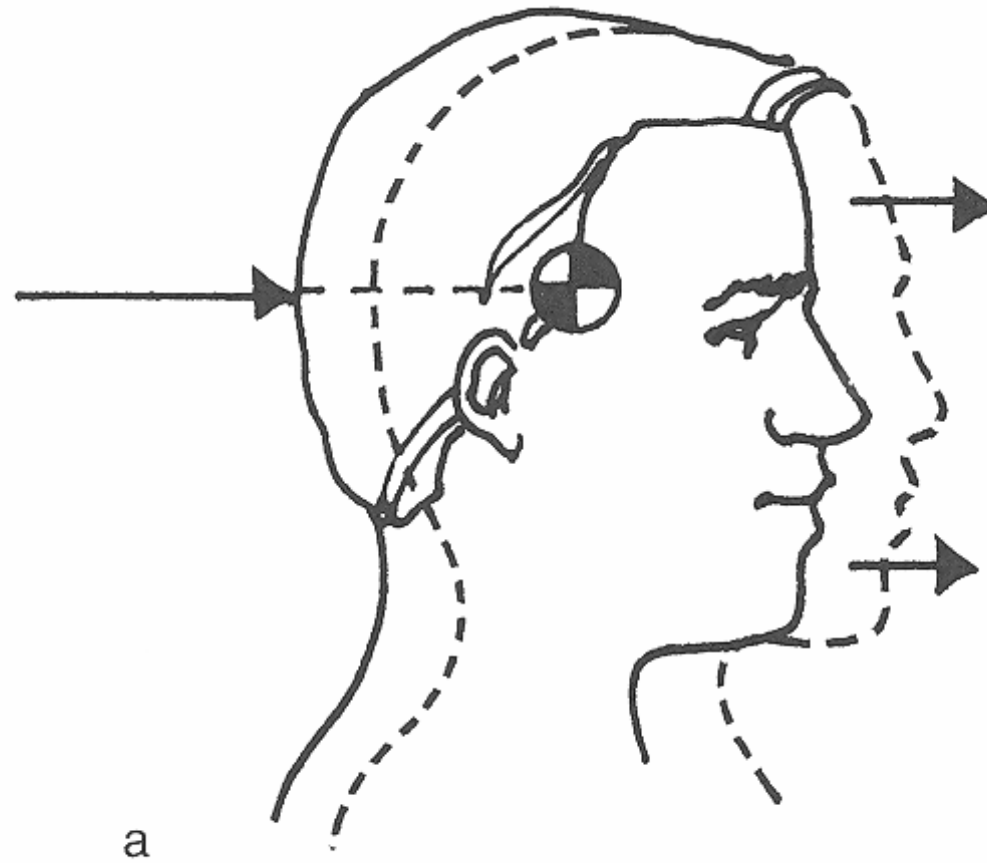
Figure 8.6 Flow chart illustrating the critical factors in the mechanics of head injury. The traumatic mechanical input is shown at the top left.

Reprinted from Ommaya & Gennarelli 1974.

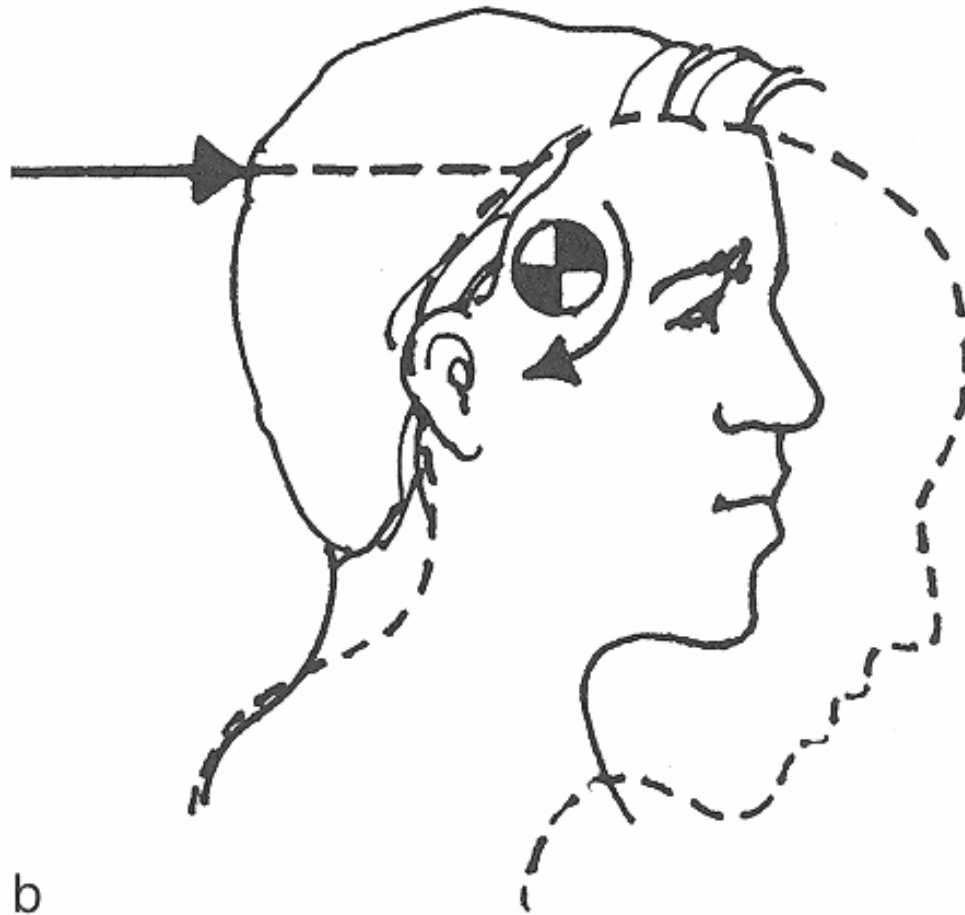


General Force Applications

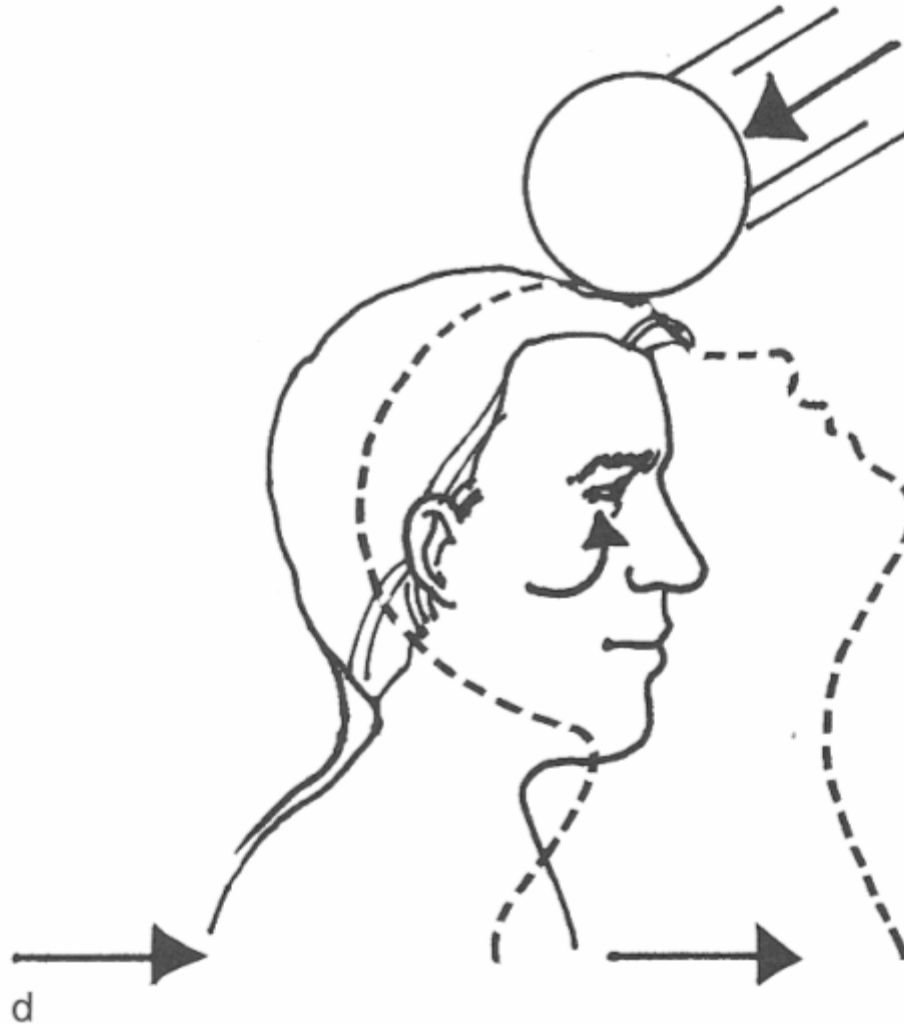
[Linear translation]



[Off-center force \rightarrow Rotation]



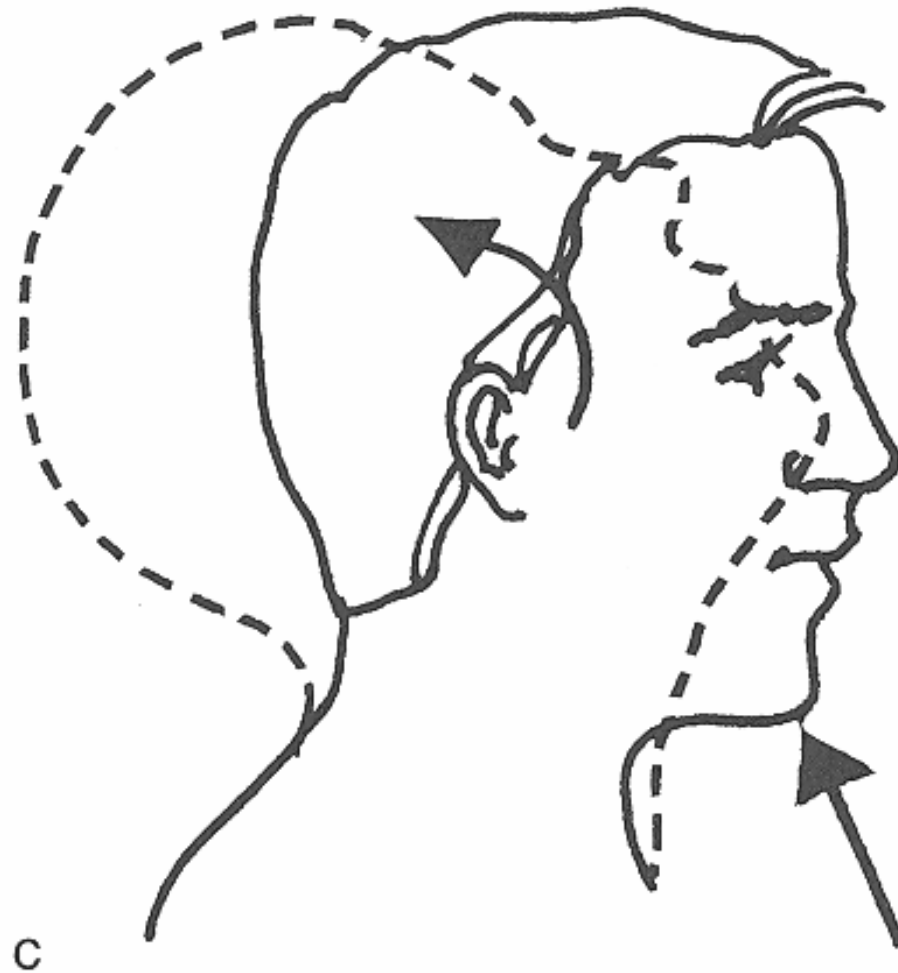
Head rotation + Body translation
(soccer header and push)



[Depressed skull fracture]



[Rotation – boxing upper cut]



[Boxing]

- Hand, wrist, face, brain injury risk
- 650 deaths worldwide in last century
 - Note: higher injury rates in college football, scuba diving, motorcycle racing, hang gliding, skydiving, horse racing
- Devastating cumulative neurological injuries
 - “Dementia pugilistica”

[Skull Fracture]

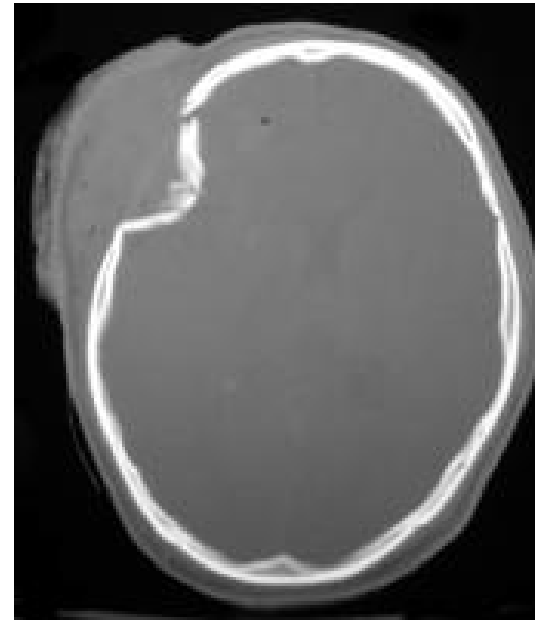
- Usually blunt trauma
- Deleterious consequences of the fracture itself are typically minimal
 - What matters is what's underneath
 - Cerebral contusions
 - Intracranial hemorrhage
 - Exposure to contaminants
 - Can show up later, after the initial CT scan

[Fracture locations]

- Along the convexity, or vault, of the skull
 - Low-velocity, blunt trauma
- Through the skull base
 - High-velocity and acceleration

[Depression]

- May tear dura mater
- Increases likelihood of hemorrhage in subarachnoid space



Cerebral Concussion and Contusion

- 1941 concussion definition: “Traumatic paralysis of neural function in the absence of lesions”
- Almost always acceleration or deceleration mechanism with direct blow to head
 - Not necessarily high F .
 - Typically α , not a

[Accelerations]

- $\alpha \rightarrow$ diffuse, widespread injury
- $a \rightarrow$ focal injury only

[Contusion mechanisms]

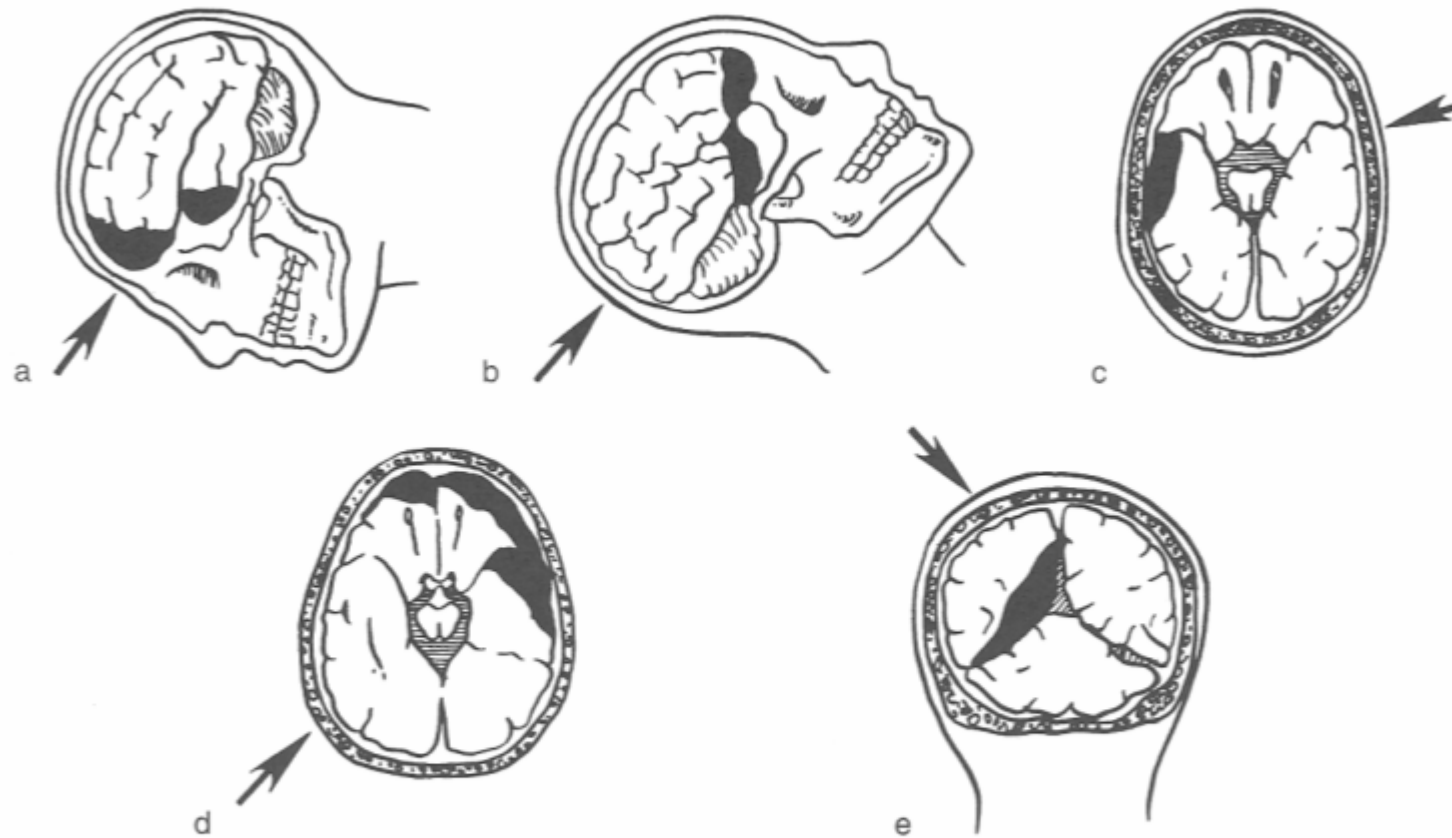
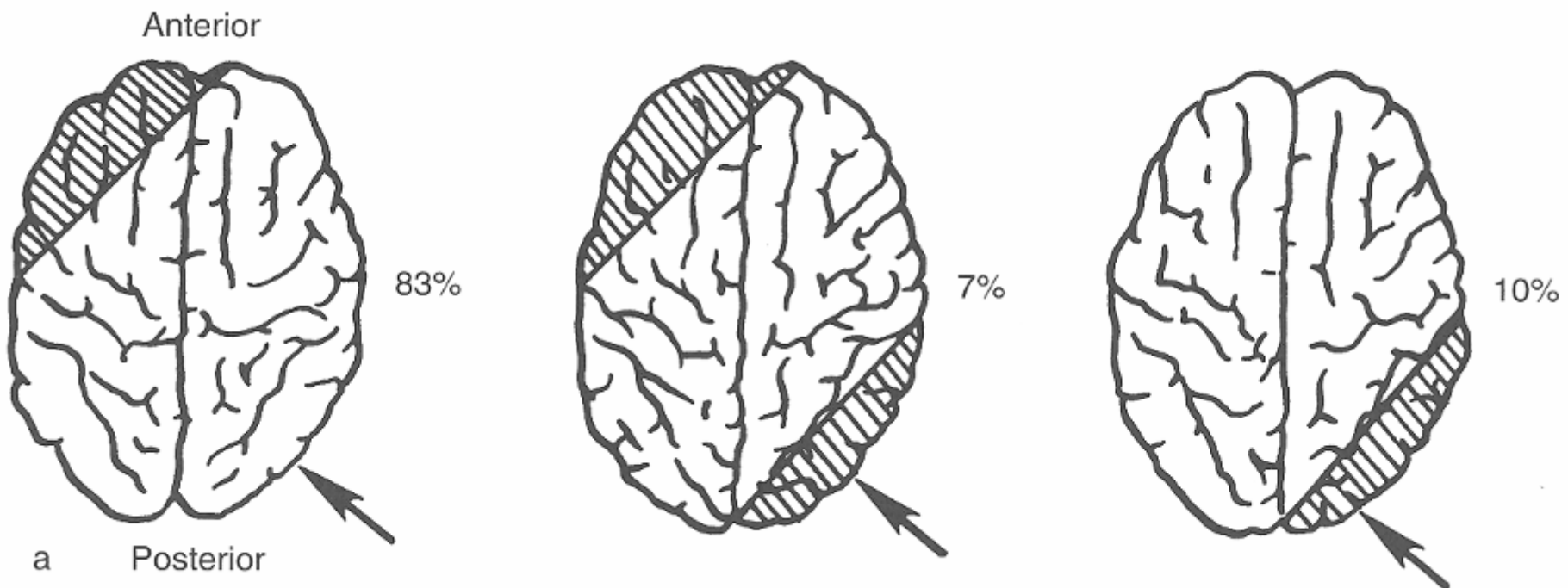


Figure 8.7 Mechanisms of cerebral contusion. Arrows show application point and direction of applied force. Shaded areas indicate location of contusion. (a) Frontal impact with frontotemporal contusion. (b) Occipital impact with frontotemporal contusion. (c) Lateral impact with contralateral temporal lobe contusion. (d) Temporo-occipital impact with contralateral frontotemporal contusion. (e) Vertex impact with diffuse medial temporo-occipital contusion.

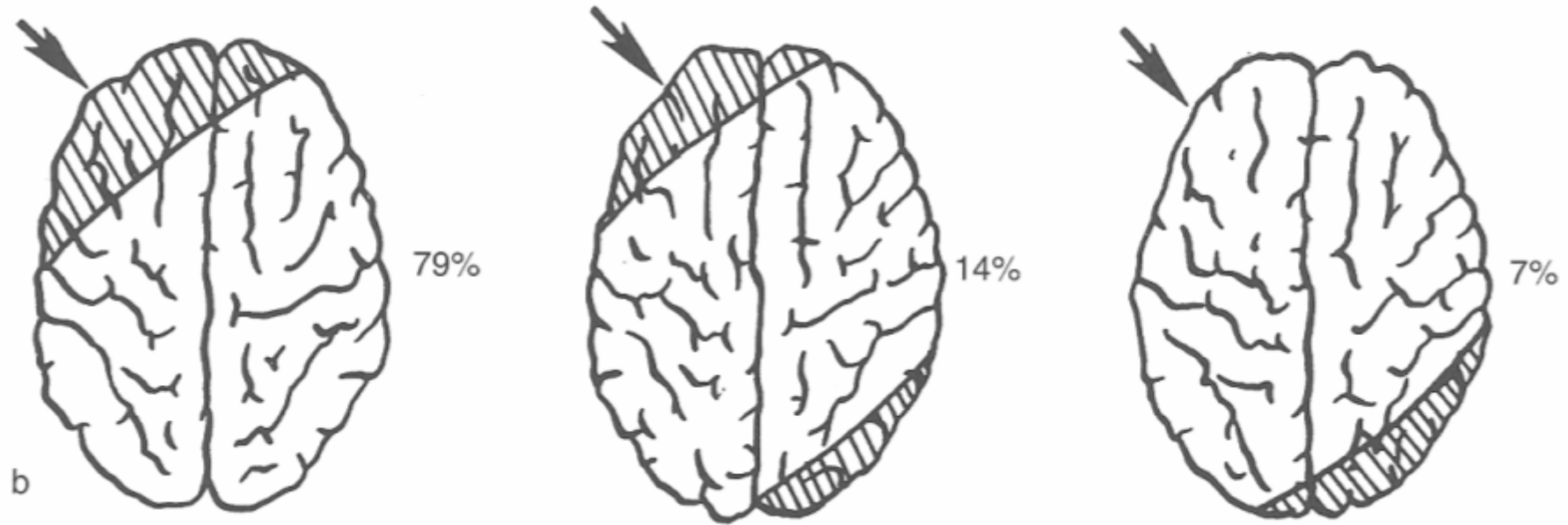
[Coup or contrecoup]

- Coup: contusion directly beneath the site of impact
- Contrecoup: contusion opposite the impact location
- Why?
 - “The inertia of the malleable brain, which causes it to be flung against the side of the skull that was struck, to be pulled away from the contralateral side, and to rotate against bony promontories within the cranial cavity explains these coup-contrecoup contusions.” Adams and Victor 1993

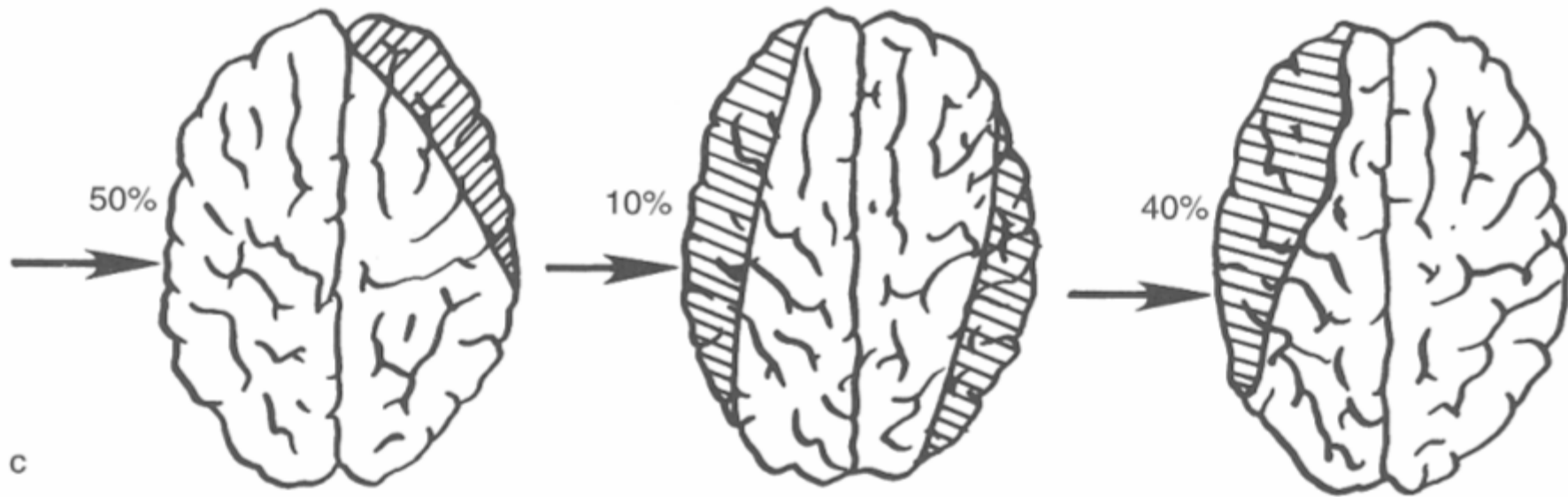
[63 fatalities: Occipital impacts]



[Frontal impacts]

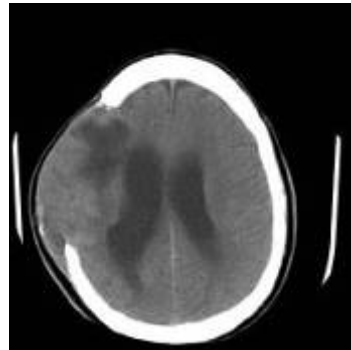


[Lateral impacts]



[Secondary injury]

- Brain swelling → increased intracranial pressure →
 - Compromised neurovascular function
 - Cerebral ischemia
 - Herniation into adjacent intracranial spaces



[More severe injury]

- Diffuse Axonal Injury
 - Concussion feature is absence of detectable pathology
 - DAI shows damage to neural structures
 - Usually shear strain from angular acceleration of head
 - Most severe are frontal plane α .



Penetrating Injury

[Definition]

- Usually, an object has pierced the cranium and has exposed the contents of the cranial vault

[Categories]

- Missile

- Bullets, shrapnel
- Vast majority

- Non-missile

- A.K.A. perforation
- Knives, nails, keys, car antennas, arrows

[Ballistics

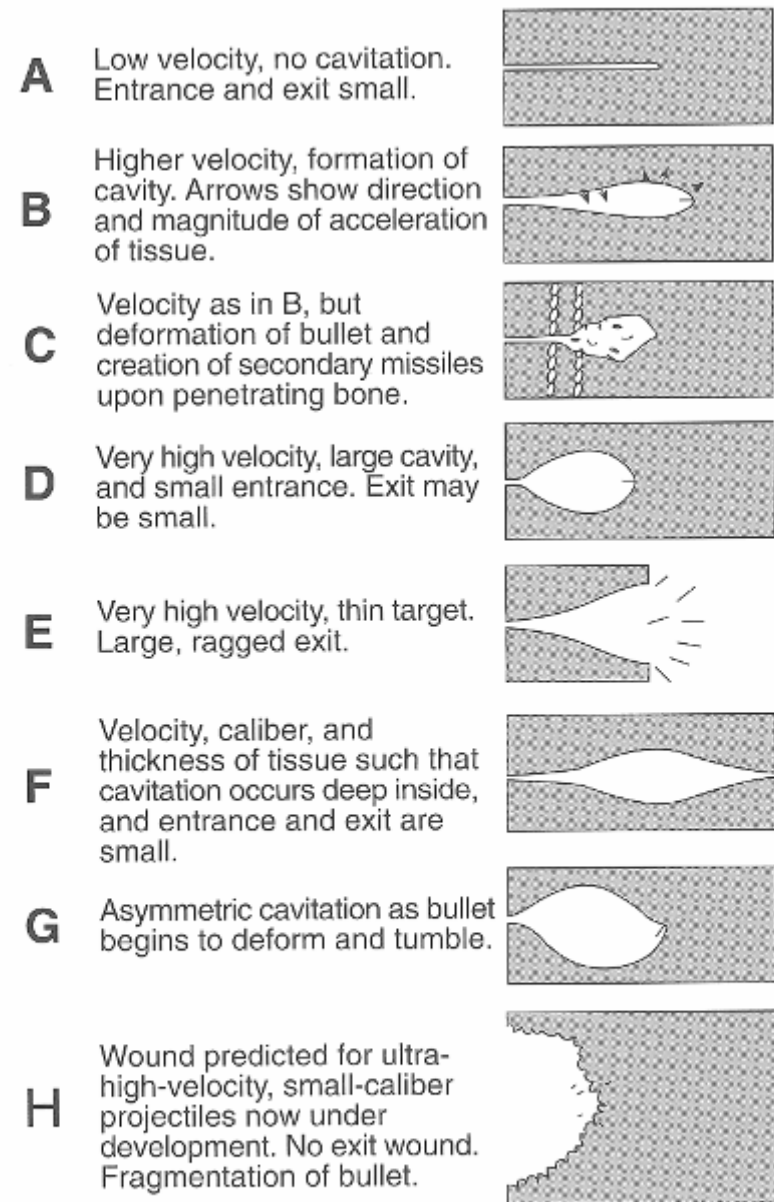


Figure 8.8 Variations of ballistic effects on animal tissue. Adapted from Swan & Swan 1989.

[Facial Fractures]

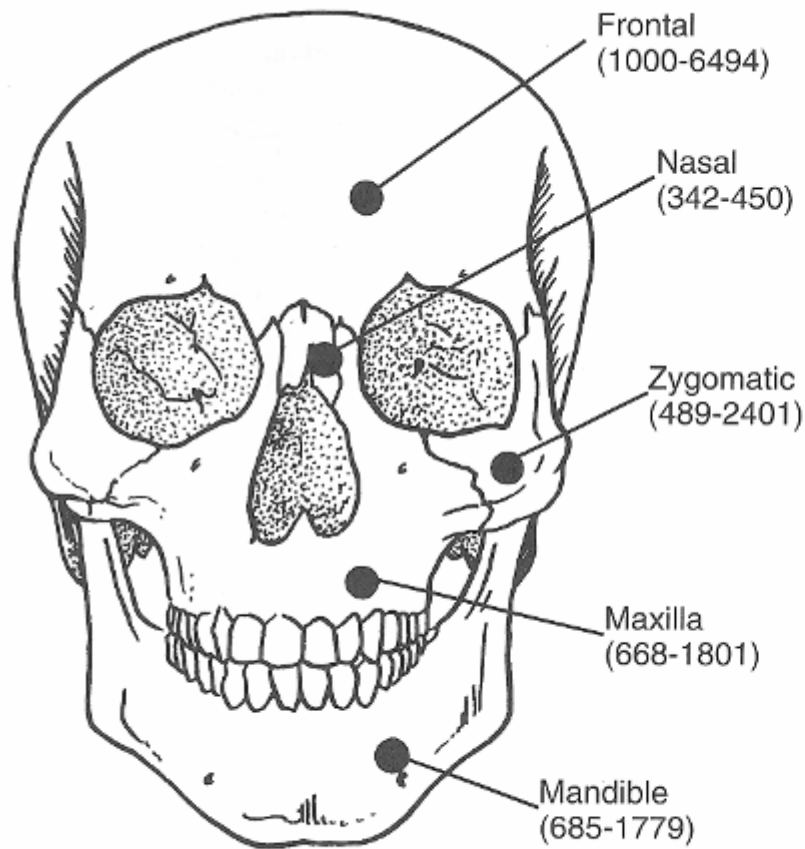
- Neurological injury associated with facial fracture as high as 76% of the time
- Usually forceful blunt trauma
 - Another person
 - An implement (hockey stick, baseball bat)
 - A projectile (golf ball)
 - An unyielding surface (steering wheel)

[Seat belts and airbags]

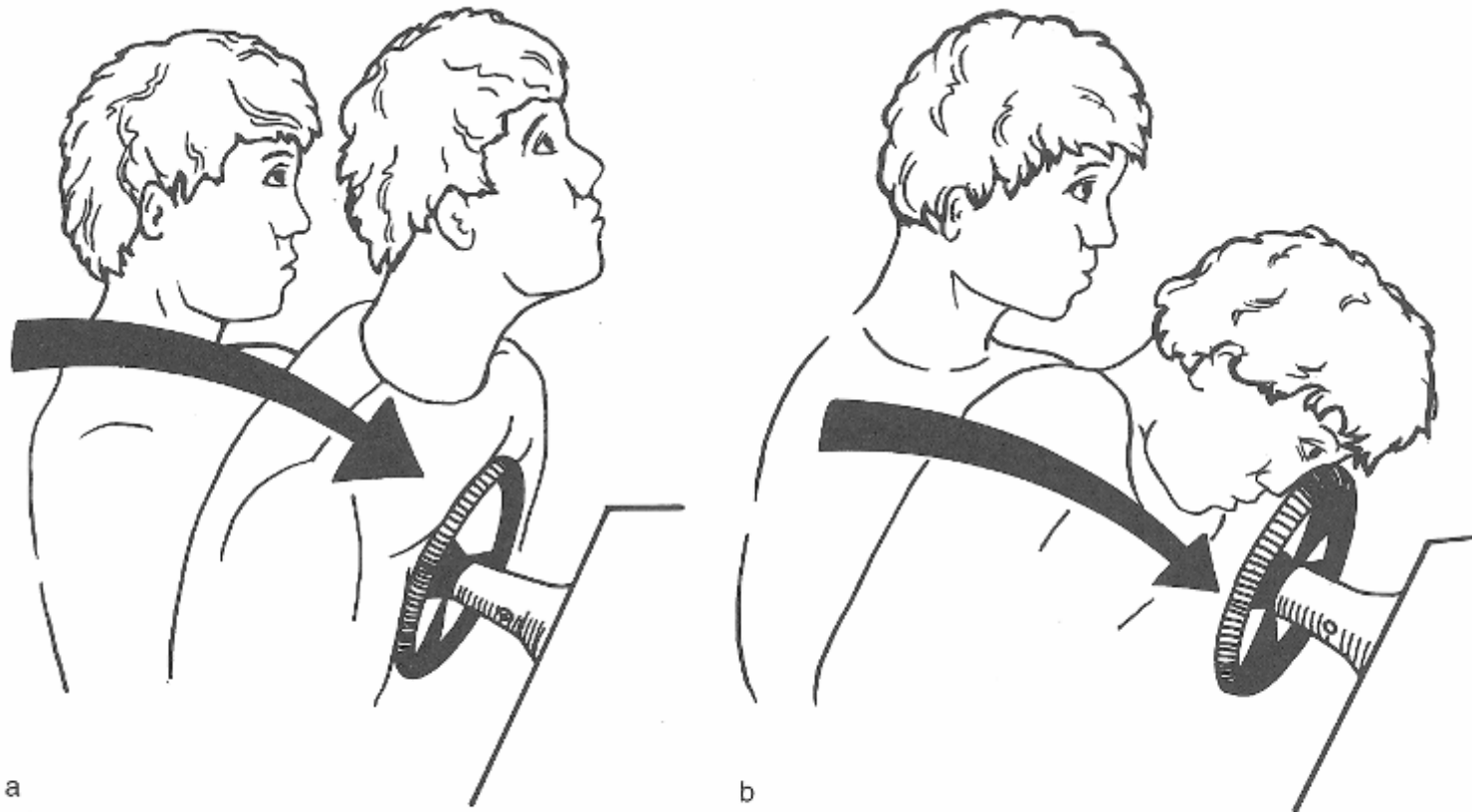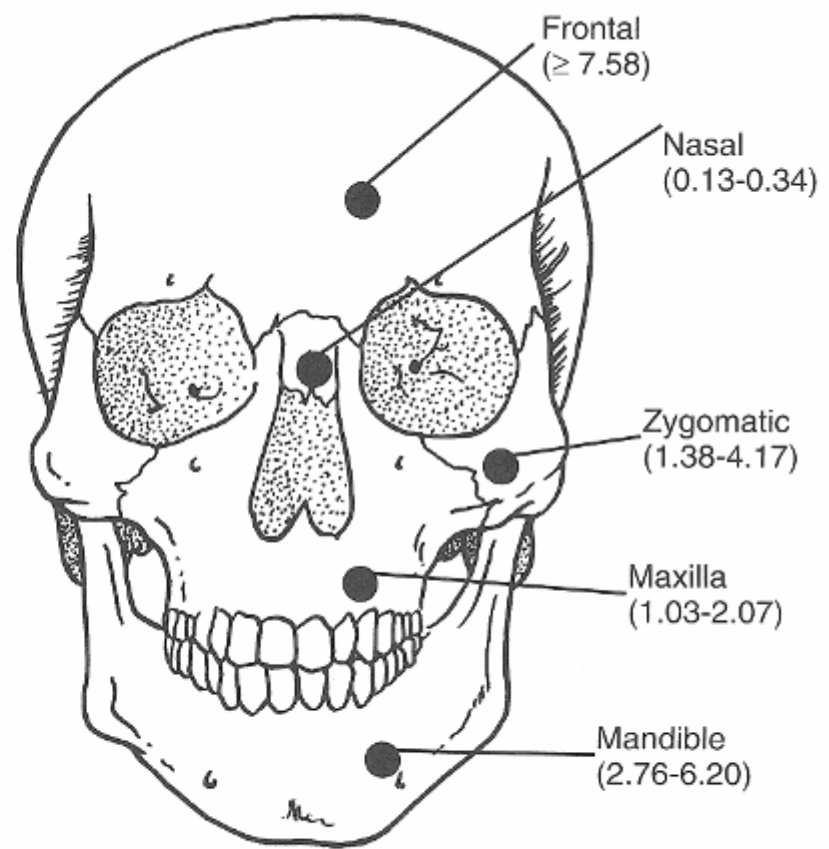


Figure 8.9 (a) Unrestrained driver thrown chest first into the steering column. (b) The torso of a driver restrained by a lap seat belt rotates forward and results in head impact with the steering wheel assembly.

[Facial bone F and P tolerance]



Force tolerance(N)



Pressure tolerance
($N \cdot mm^{-2}$)



Neck Injury

[Must consider the spinal cord]

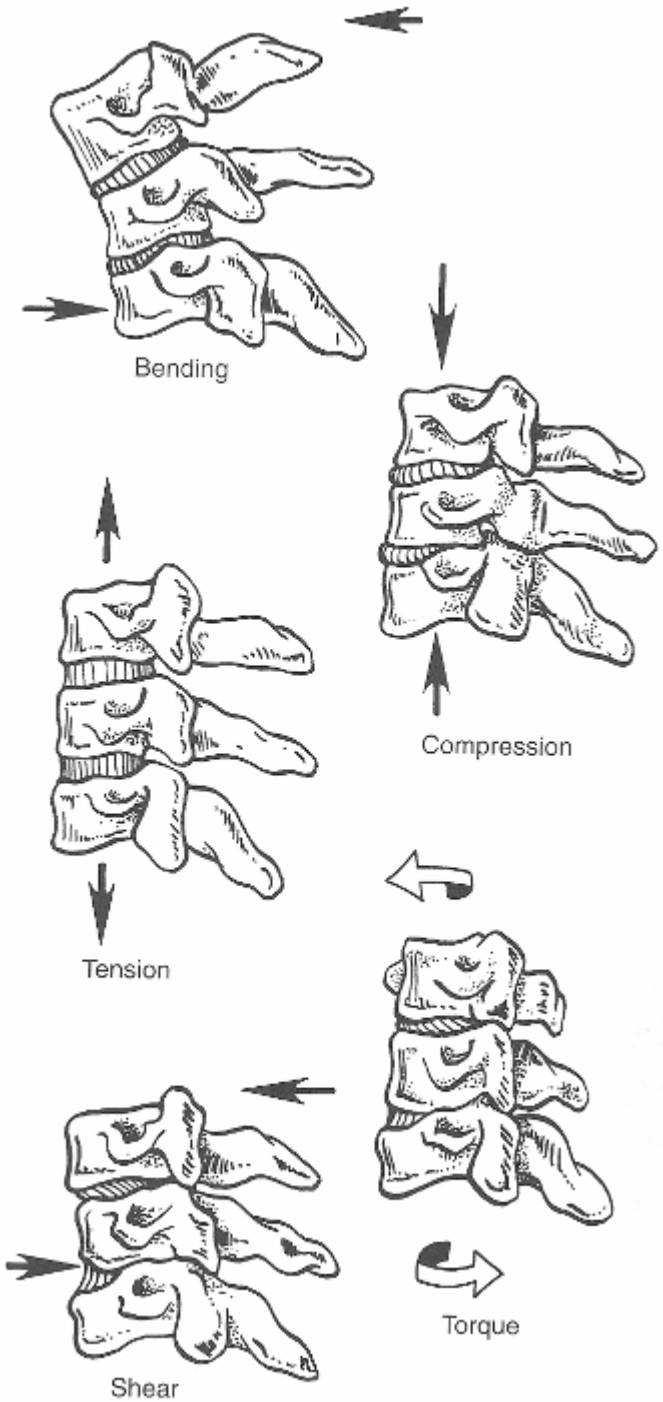
- At neck, level is vital
 - C3-C4: paralysis of trunk and extremities, loss of unassisted respiration
 - C5-C6: limited arm movement
 - C7-T1: maybe just LE paralysis

[Location]

- Not only is location important because of level of spinal cord, but also...
 - Overall motion of head WRT trunk may not be indicative of local motion between adjacent segments
 - Small deviations (<1cm) in the point of force application or head position can change injury mechanism
 - Compression-flexion vs. compression-extension, e.g.

[Loading mechanisms

- Reminder!



[Flexion-compression]

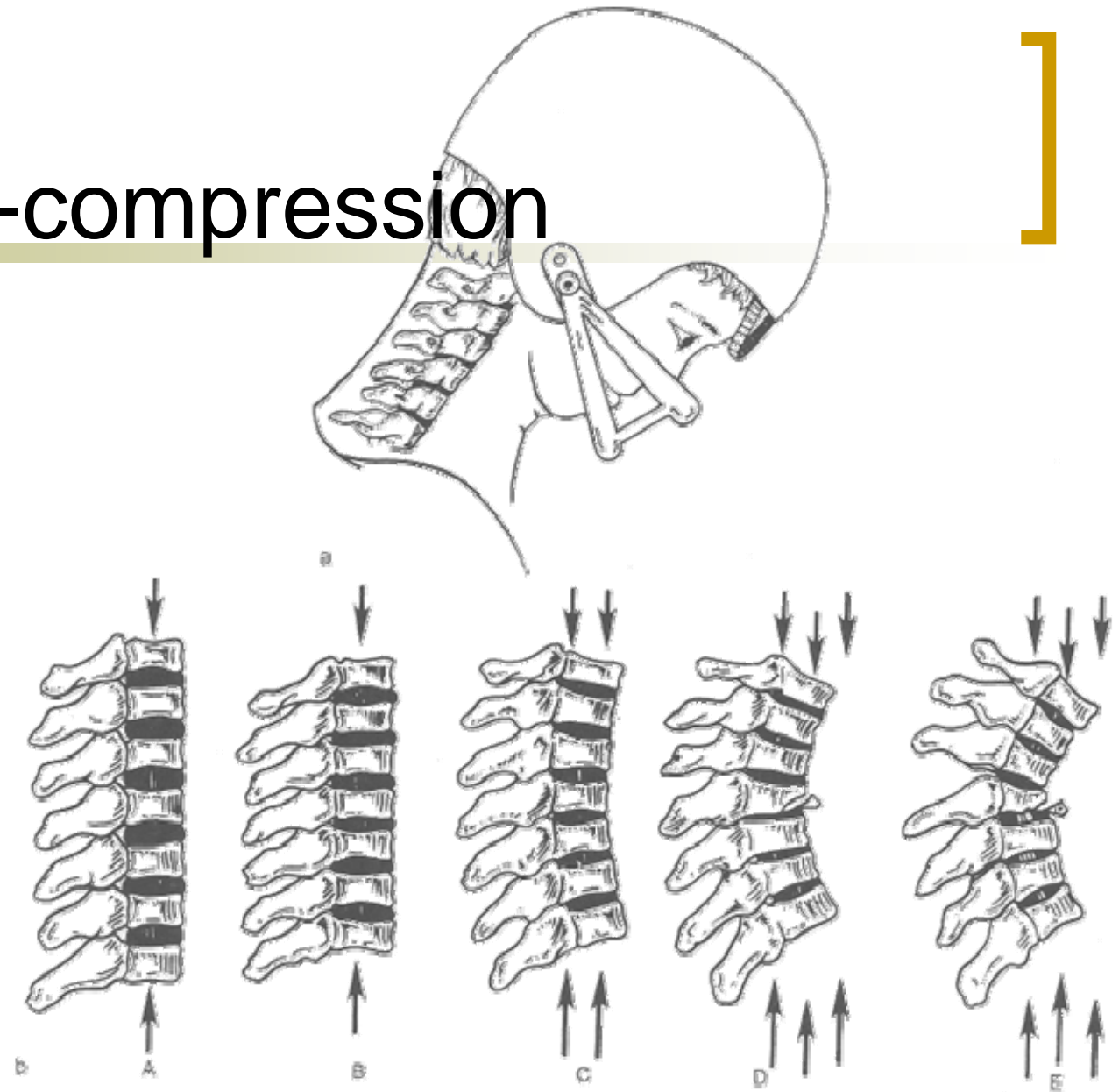


Figure 8.17 (a) With the neck slightly flexed (approximately 30°), the cervical spine is straightened and functions as a segmented column. (b) Axial compressive forces applied to a segmented column (A) initially compress the column (B). Increased loading causes angular deformation (C), buckling (D), and eventual fracture, subluxation, or dislocation (E). Reprinted from Torg et al., 1990.

[Loading on vertebra]

- Flexion-compression can also cause shear fracture at anteroinferior corner of cervical vertebral body
 - “Teardrop” fracture
 - Also from extension, can be combined with sagittal fractures

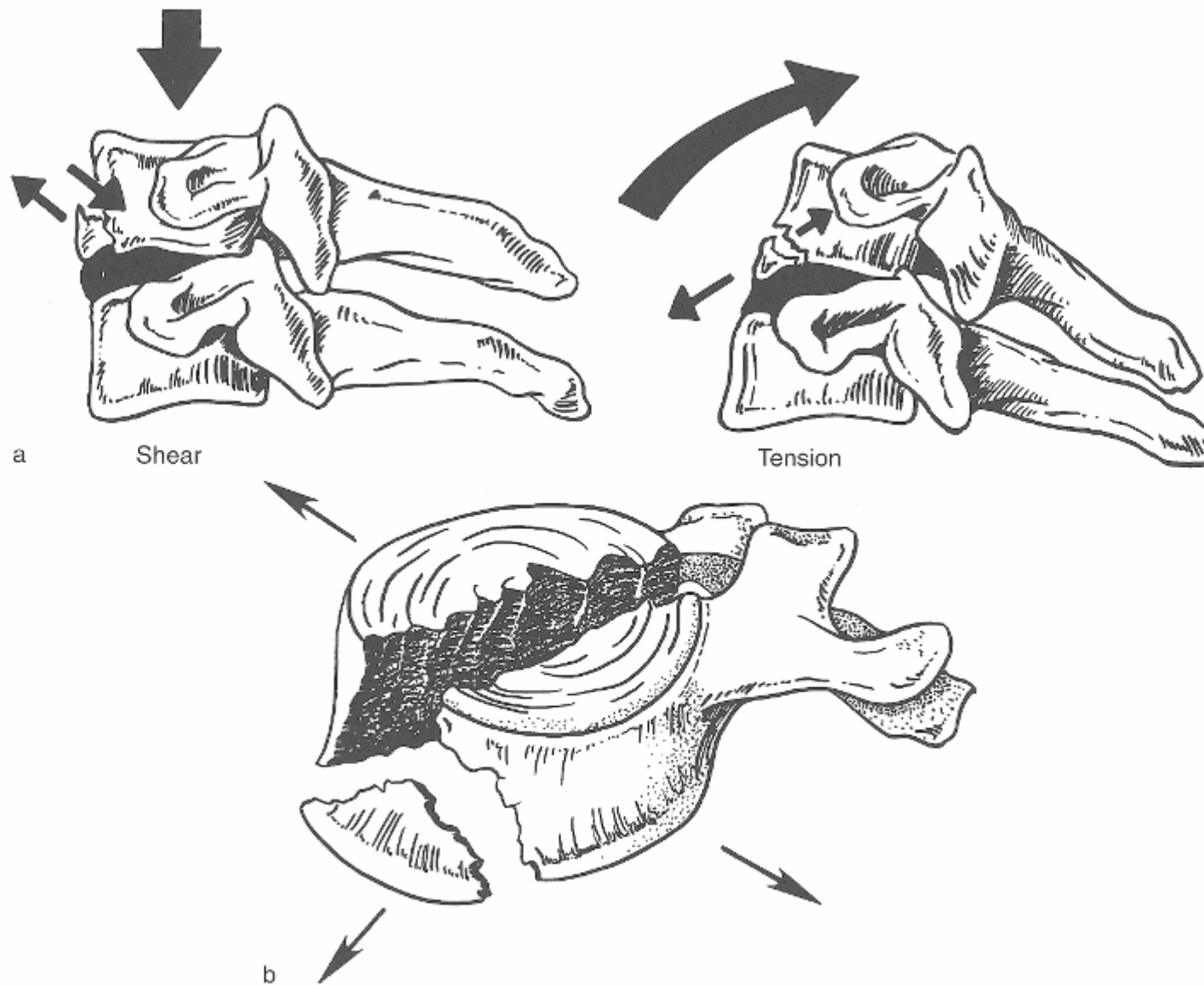


Figure 8.18 Teardrop vertebral fractures. (a) Bone fragment fracture at the anteroinferior border of the vertebral body resulting from compressive loading (*left*) that results in shearing at the fragment interface (dark arrows) or from spinal extension (*right*) that creates tensile loading at the fragment interface. (b) A three-part, bipplanar teardrop fracture with an anteroinferior corner fracture fragment and a sagittal fracture through the vertebral body.

Extension-Tension Injury

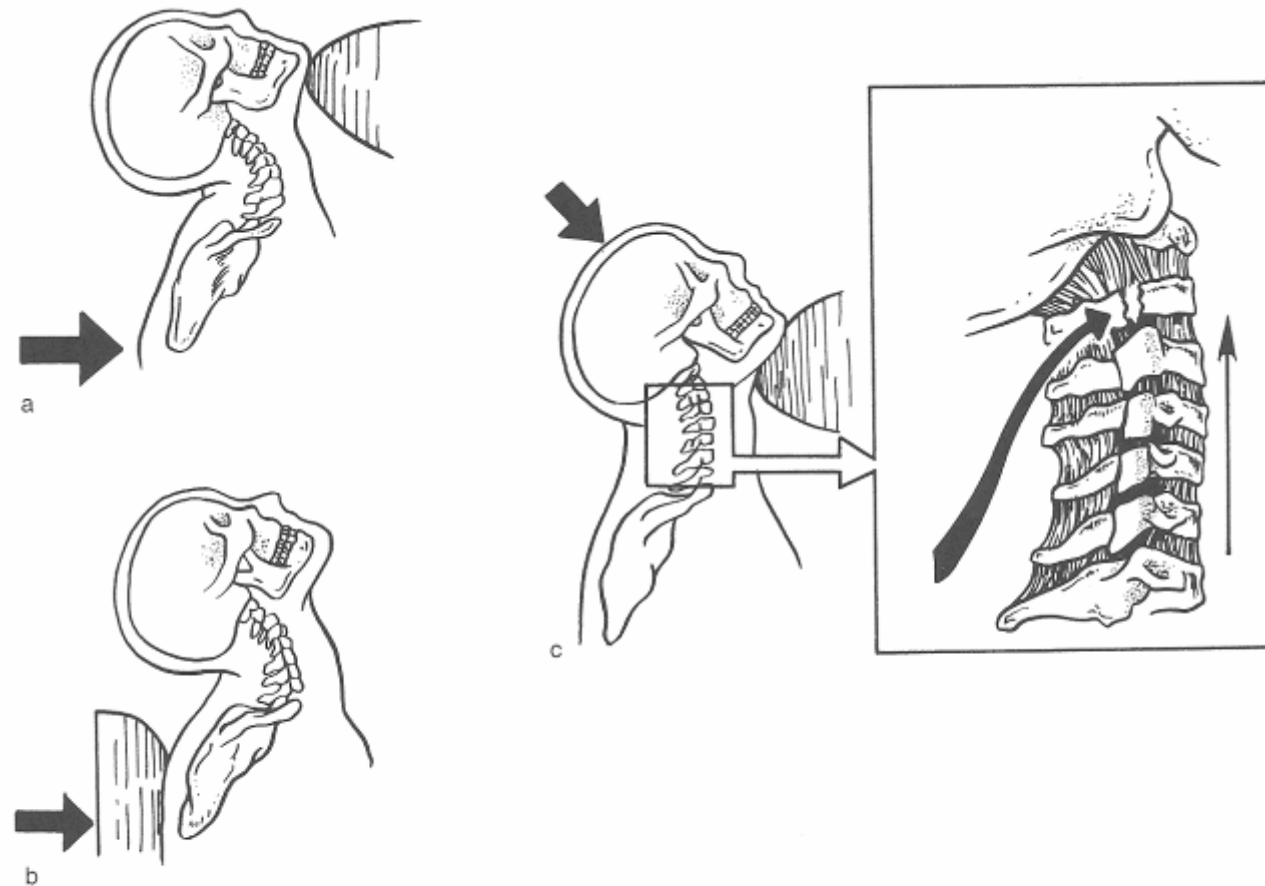


Figure 8.19 Extension-tension injury mechanisms. Cervical hyperextension caused by (a) posterior impact with forcible resistance on the chin, (b) inertial forces from posterior impact, and (c) forces applied inferiorly to the posterior aspect of the head with forcible resistance applied to the chin.

Reprinted, by permission, from SAE publication, *Head and Neck Injury* (P-276, p. 123). Copyright 1994 by Society of Automotive Engineers, Inc.

[Whiplash]

- Newton's First Law
- Note magnification
- Note phase shift

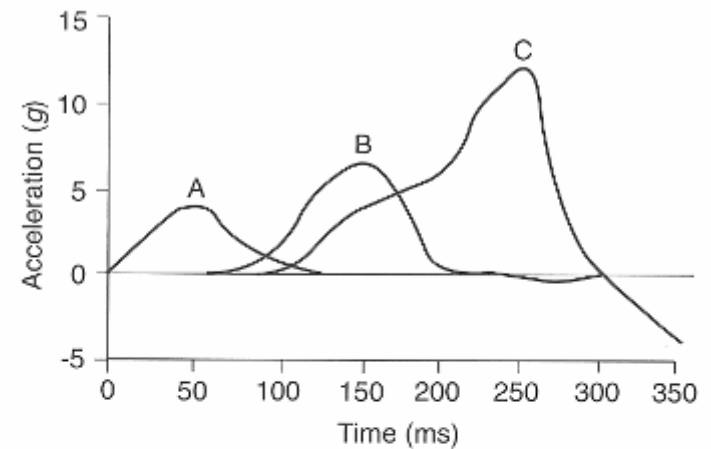
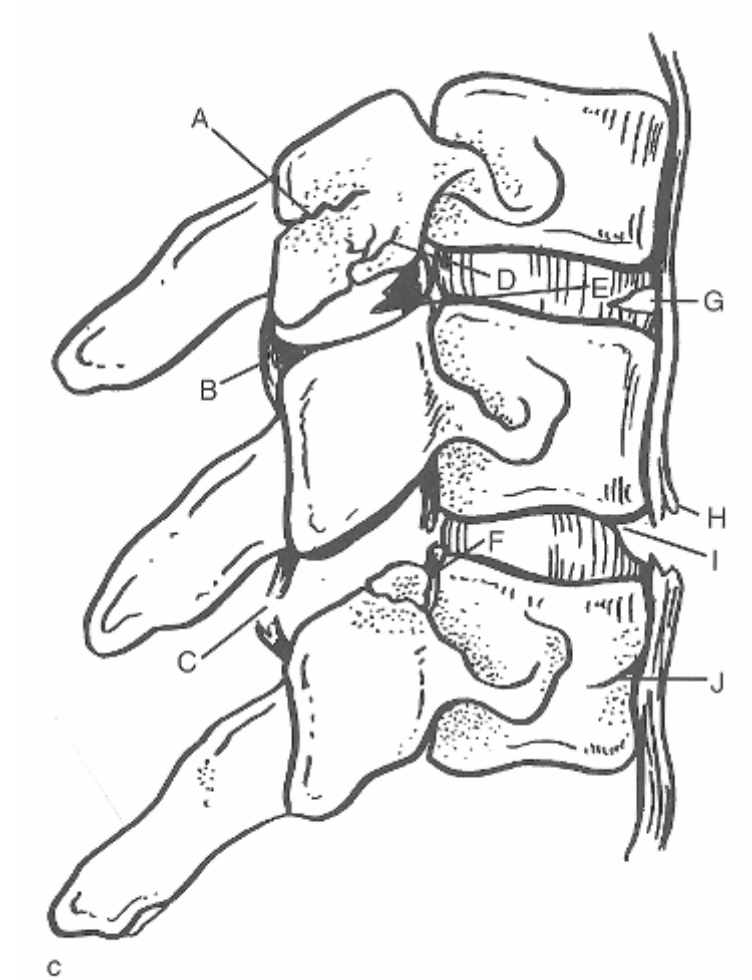


Figure 8.20 Idealized acceleration curves of (A) an impacted vehicle, (B) an occupant's shoulders, and (C) an occupant's head. As the vehicle is impacted (e.g., in an automobile rear-end collision), it accelerates first, reaching a peak acceleration of almost 5 g 's (i.e., five times the acceleration of gravity). The vehicle occupant's shoulders reach their peak acceleration of about 7 g 's 100 ms later. Finally, the occupant's head reaches its peak acceleration of greater than 12 g 's 250 ms after initial impact. This sequential progression of peak accelerations is evidence of both momentum and energy transfers.

Reprinted from Barnsley, Lord, & Bogduk 1994.

[Common whiplash lesions]



[Cervical Spondylosis]

- Degeneration of cervical IV disks and surrounding structures
 - Reduced height
 - Bony outgrowth
 - Risk of
 - spinal stenosis (narrowed canal)
 - Impingement
 - Impaired blood perfusion of spinal cord



Trunk Injuries

[Spinal Cord Risks]

- Vertebral Fracture
- Disk degeneration
- Spinal deformities
- Spondylolysis, Spondylolisthesis

[Vertebral fracture]

- Main concern is proximity to spinal cord, possible impingement
- Usual cause: axial compression
 - C-spine and
 - Thoracolumbar (T11-L3)
 - Minimal curvature
 - Transition zone between rigid T and flexible L



- “Burst fracture” (Holdsworth, 1970)
 - Body of vertebra can shatter from within
 - May cause multiaxial instability

[Role of disk degeneration]

- Compressive stresses change depending on level of disk degeneration
 - Burst fractures more dangerous with *healthy* disks



Normal Disk

Degenerated Disk

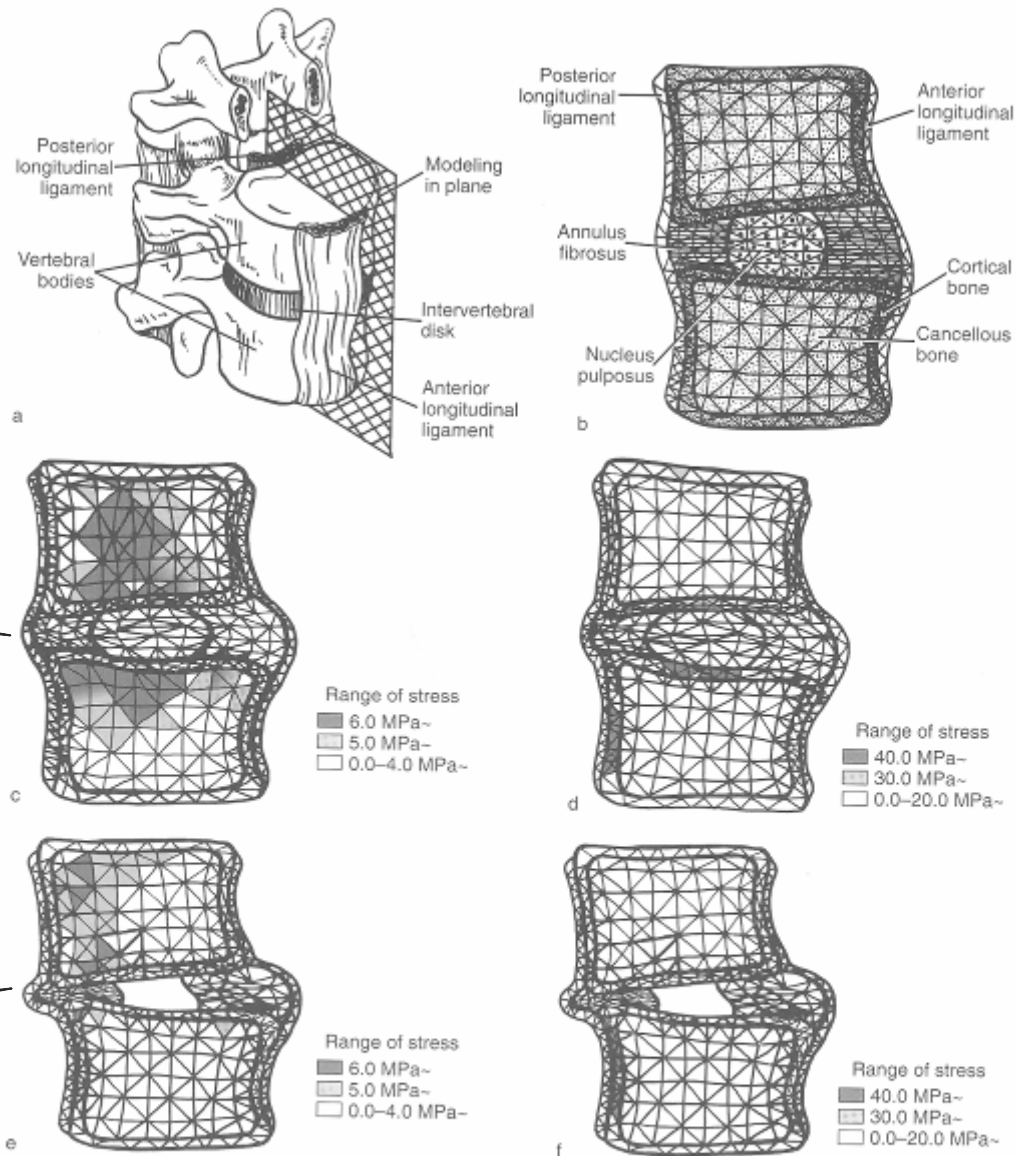


Figure 8.24 (a) Median (midsagittal) plane of modeling. (b) Finite-element plane model. (c) Stress distribution of one motion segment with a healthy disk under axial compression showing highest trabecular bone stresses under the nucleus pulposus and at the superoposterior regions, and (d) highest cortical shell stresses at the middle of the end plate and posterior wall cortex. (e) Stress distribution in a model of a severely degenerated disk shows no stresses in the trabecular bone under the nucleus, and (f) highest stresses in the cortical bone of posterior wall.

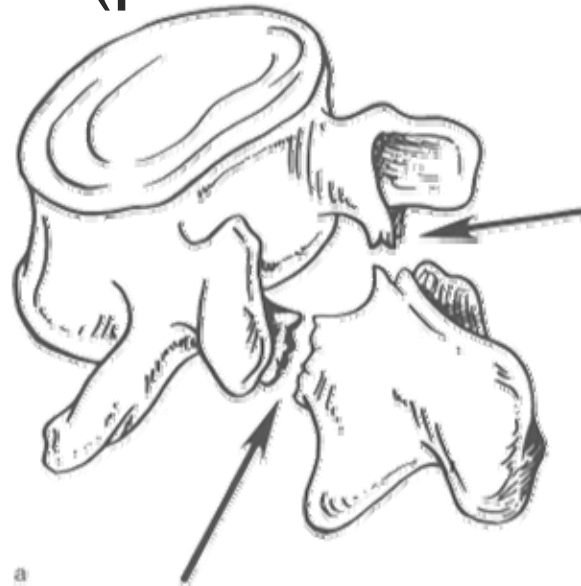
From "Influence of disc degeneration on mechanism of thoracolumbar burst fractures" by O. Shirado, K. Kaneda, S. Tadanu, H. Ishikawa, P.C. McAfee, & K.E. Warden, 1992, *Spine*, 17(3) (Fig. 1, p. 287; Figs. 5 & 6, p. 291). Copyright 1992 by Lippincott-Raven. Adapted by permission.

[Spinal deformities]

- Scoliosis
 - Frontal plan curvature
 - Transverse outcomes as well
 - Orthotic treatment can slow progression but not correct
- Kyphosis
 - Excessive sagittal thoracic curvature

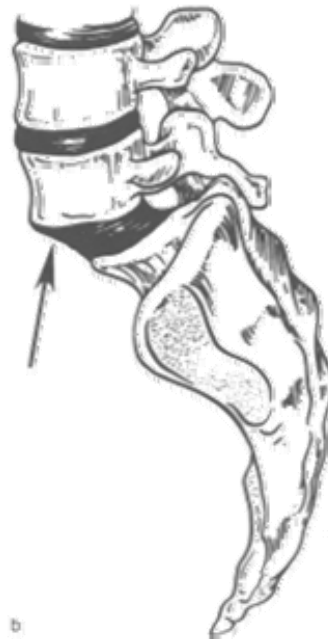[Spondylolysis]

- Defect in the area of the lamina between the superior and inferior articular facets (pars interarticularis)



[Spondylolisthesis]

- Translational motion, or slippage, between adjacent vertebral bodies



[The Spondylos]

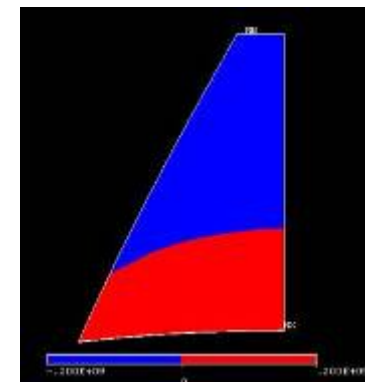
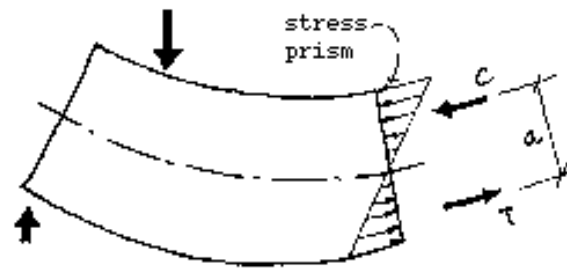
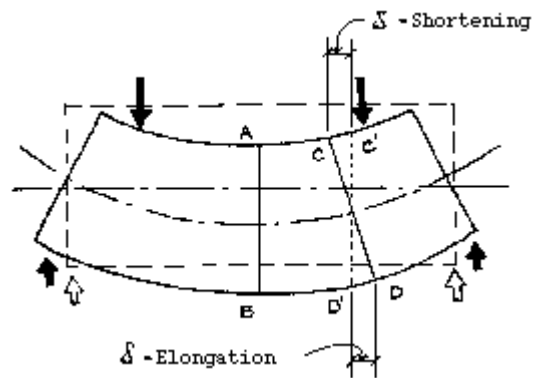
- Especially affect young and athletic populations
- Five types
 - Dysplastic (hereditary or congenital)
 - Isthmic (succession of microfractures)
 - Degenerative
 - Traumatic
 - Pathological (e.g. infection)

Mechanisms for pars defect failures

- Repetitive spinal flexion
 - Combined flexion and extension
 - Forcible hyperextension
 - Lumbar spine rotation
-
- At risk: gymnasts, weight lifters, wrestlers, divers

[Low-Back Pain]

- A course by itself!
- An IV disk mechanics lesson: the neutral axis



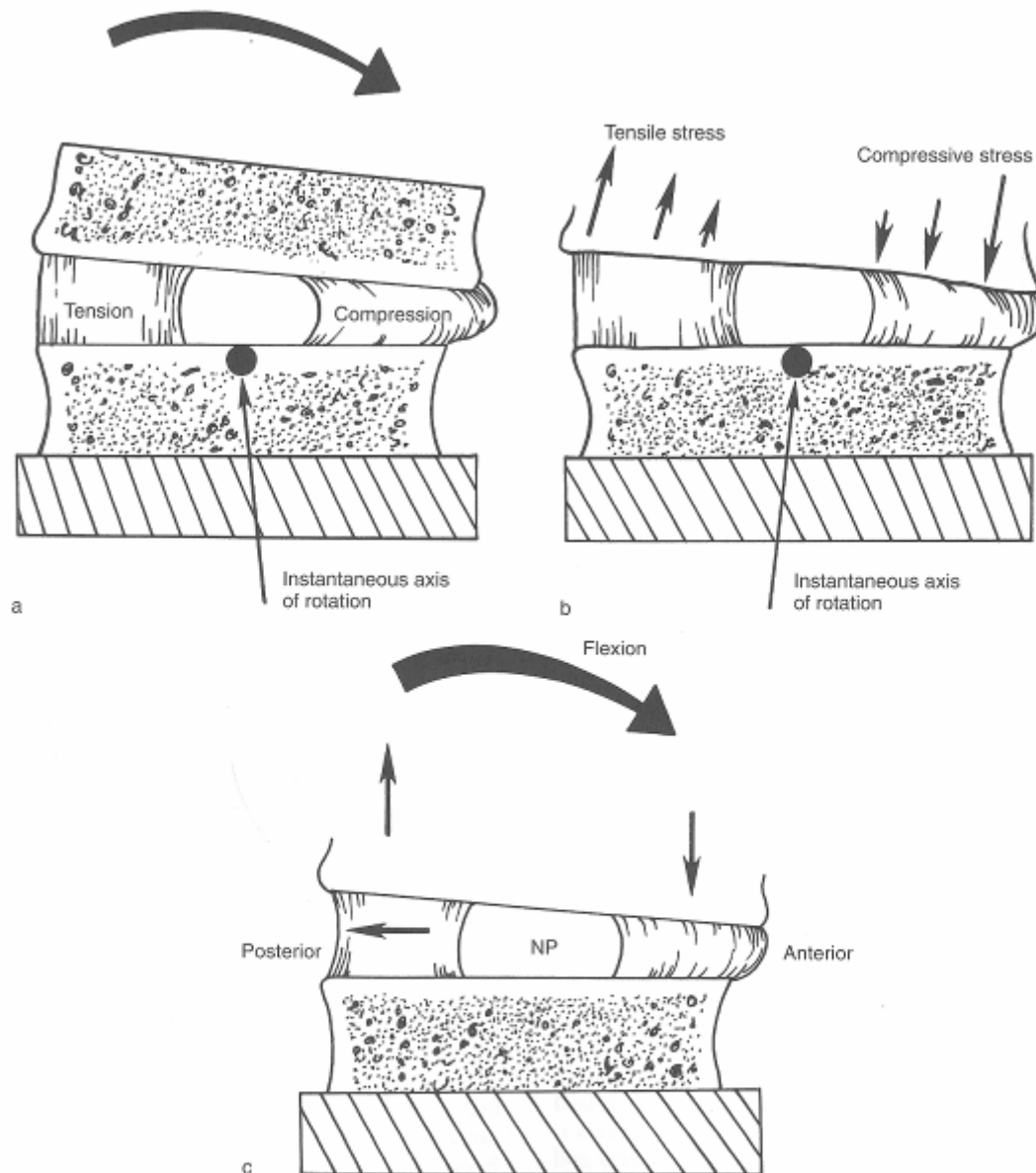


Figure 8.33 Intervertebral disk stress in response to bending. (a) In bending, one side of the disk experiences compression while the other side undergoes tension. (b) The compressive and tensile stresses are at a maximum at the outer borders of the disk and decrease toward the center of the disk. (c) Forward flexion of the spine tends to squeeze the nucleus pulposus (NP) posteriorly.

Parts (a, b) from *Clinical Biomechanics of the Spine* (2nd ed.) (Fig. 1-10, p. 15) by A.A. White & M.M. Panjabi, 1996, Philadelphia: J.B. Lippincott Company. Copyright 1990 by Lippincott-Raven. Adapted by permission.

[IV disk pathology]

- Sprain (annular fibers)
- Fluid ingestion by NP
- Annulus disruption
- Bulging disk
- Sequestered fragment (from AF or NP into joint space)
- Degenerating disk

[Low back pain]

- Affects 80% of the population
- 85% never specifically diagnosed


[Conclusion]

- LE was important because:
- UE was important because:
- Head/neck/trunk are important because:


Greatest potential for catastrophic injury

Interesting Injury Cases

Head Trauma
Shoulder Reduction




Head Trauma Cases




Massive Trauma – Automobile Accident

Post-op CT film to monitor bone
growth



Head-Penetration Injury

The curious case of Phineas
Gage





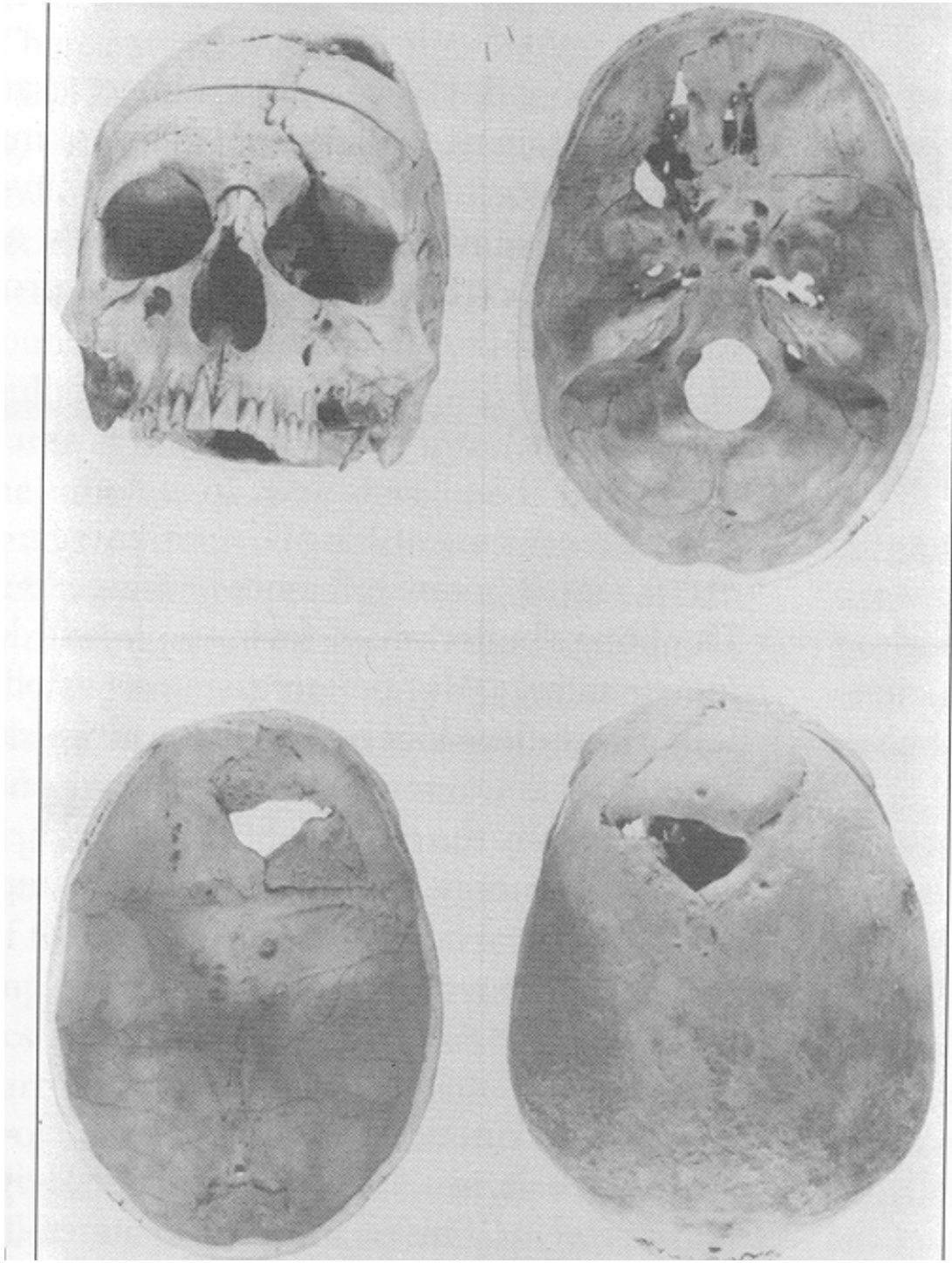
Poor Phineas

- 25 y/o railroad construction foreman
- Mid-19th century Vermont
- Placing explosives to blast stone from the path of the Rutland & Burlington Railroad
- Using an iron rod to tamp blasting powder into a hole
 - 13 lb, 1.25 inches in diameter, 3.5 feet long




- Powder exploded prematurely, launching rod 100 feet away, and through Gage's head in the process.





“The rod landed more than 100 feet away, covered in blood and brains. Phineas Gage has been thrown to the ground. He is stunned, in the afternoon glow, silent but awake.”

Damasio 1994



Free Soil Union (Ludlow, Vermont), September 14, 1848



“The powder exploded, carrying an iron instrument through his head an inch and a fourth in circumference, and three feet and eight inches in length, which he was using at the time. The iron entered on the side of his face, shattering the upper jaw, and passing back of the left eye and out at the top of his head. The most singular circumstance connected with this melancholy affair is, that he was alive at 2 o'clock this afternoon and in full possession of his reason, and free from pain.”

Mr Joseph Larkin Austin, eldest son of Mr Eleazer Austin, was found drowned near the south bridge in Salem; it is supposed he fell overboard between 2 and 3 o'clock in the morning, while fishing.

Horrible Accident.—As Phineas P. Gage, a foreman on the railroad in Cavendish, was yesterday engaged in tamping for a blast, the powder exploded, carrying an iron instrument through his head an inch and a fourth in circumference, and three feet and eight inches in length, which he was using at the time. —The iron entered on the side of his face, shattering the upper jaw, and passing back of the left eye, and out at the top of the head.

The most singular circumstance connected with this melancholy affair is, that he was alive at two o'clock this afternoon, and in full possession of his reason, and free from pain —*Ludlow, Vt., Union.*

The chief of the Philadelphia dogkillers, a black man named George Horsey, attempted to kill his wife. He broke into her room armed with a pistol and knife; she threw herself out of the second story window to escape, breaking her leg in the fall; he pursued her, and attacked and injured her severely. She was taken to the hospital. Horsey was fully committed for trial.



The Cure

- Gage was pronounced fully cured within two months of the accident
- No difficulty walking, touching, hearing, or speaking



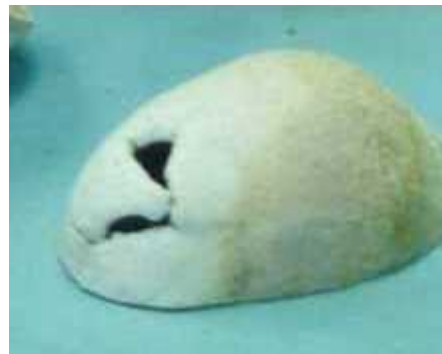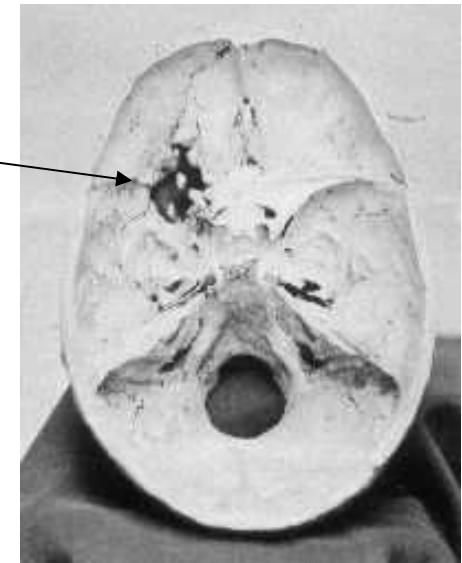
BUT

- Gage was “not the same Gage”
- No longer a conscientious worker
- Progressive alterations in personality, social reasoning skills
- More combative, vulgar
- Eventual epileptic seizures, died 11.5 years later
- Implications on brain centers then unknown



The Damage

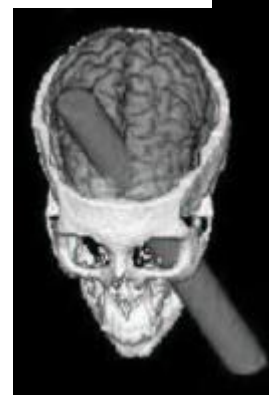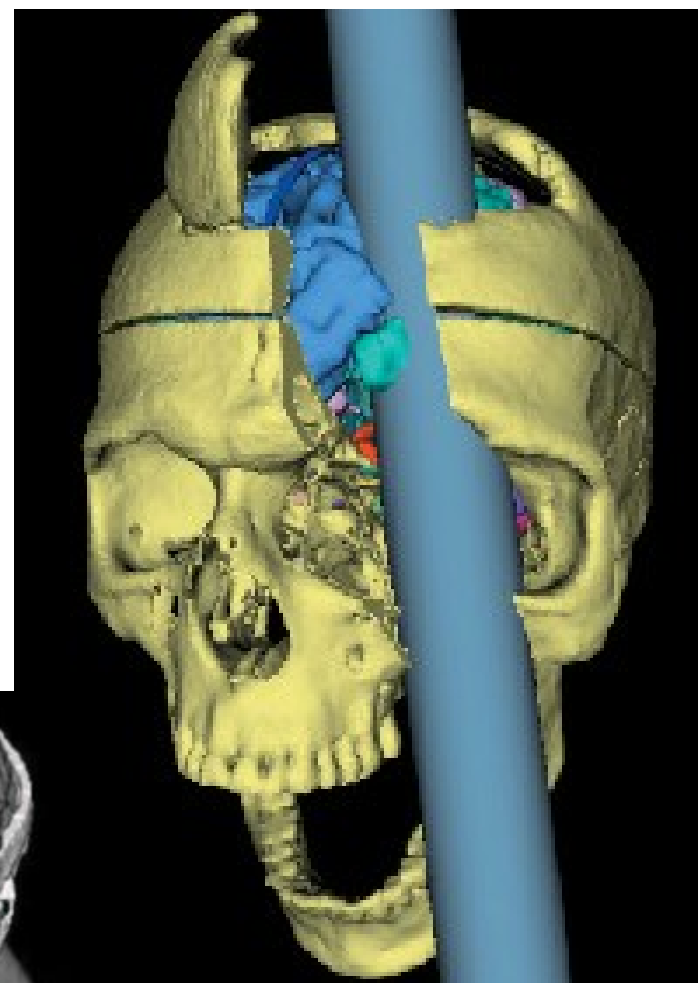
- Small area under the zygomatic arch where the tamping iron first impacted
- Orbital bone
- Exit: frontal and parietal bones
 - Total area 3.5"x2"
 - Mostly reconstructed






Recreations, Scenarios

- “Hinged Skull” scenario: soft tissue contained a hinge of skull fragment that was closed immediately following the insult
- P. Ratiu, I-F Talos, S. Hawker, D. Lieberman, and P. Everett. (2004). The tale of Phineas Gage, Digitally remastered. *Journal of Neurotrauma*, 21, 637-643.



Reducing Shoulder Dislocations

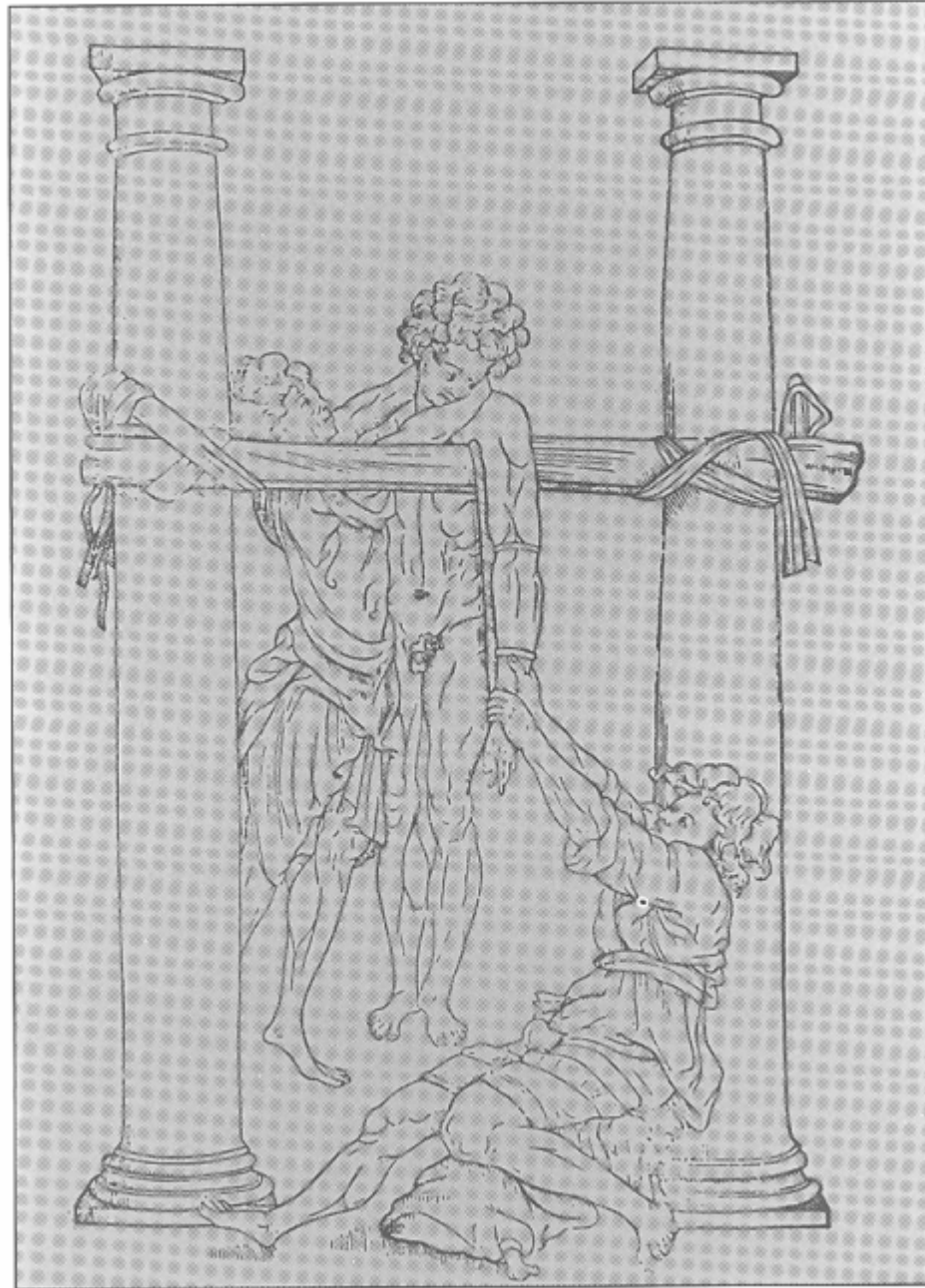
Hippocrates, pg. 4



Hippocrates (460-377 BC),



- Traction reduction:
 - injured arm placed in slight abduction
 - downward/adduction forces applied to the arm, while counter-traction is applied
 - counter-traction (still used) provided by the surgeon's foot placed in the patient's axilla
 - Alternative methods described by Hippocrates:
 - placing the affected arm over a variety of objects, including a long stick, a ladder rung, or the back of a chair and pulling down using gravity as counter-traction.
 - surgeon places his shoulder in the patient's axilla, then lifts the patient up while holding the affected arm. Hippocrates stated that, for success, the surgeon required a certain amount of strength and that he needed to be taller than the patient.



—
—
—





16th Century: Ambroise Paré

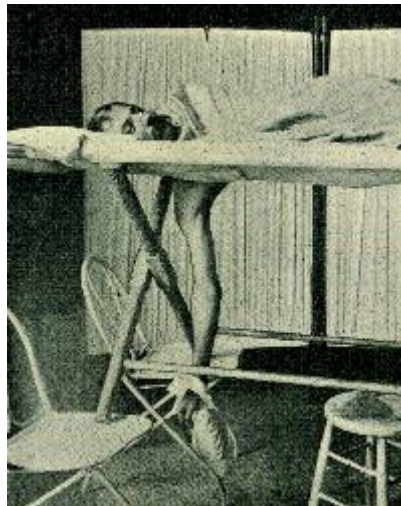

- Ladder Method
 - Mount patient on a stool next to a ladder
 - Bind sound arm and legs
 - Place affected arm through rung of ladder
 - Remove stool
 - Notes: caution against “breaking shoulder bone”
 - Ensure patient does not place head through rungs “lest he break his neck”

Stimson (1905) Hanging Arm Technique



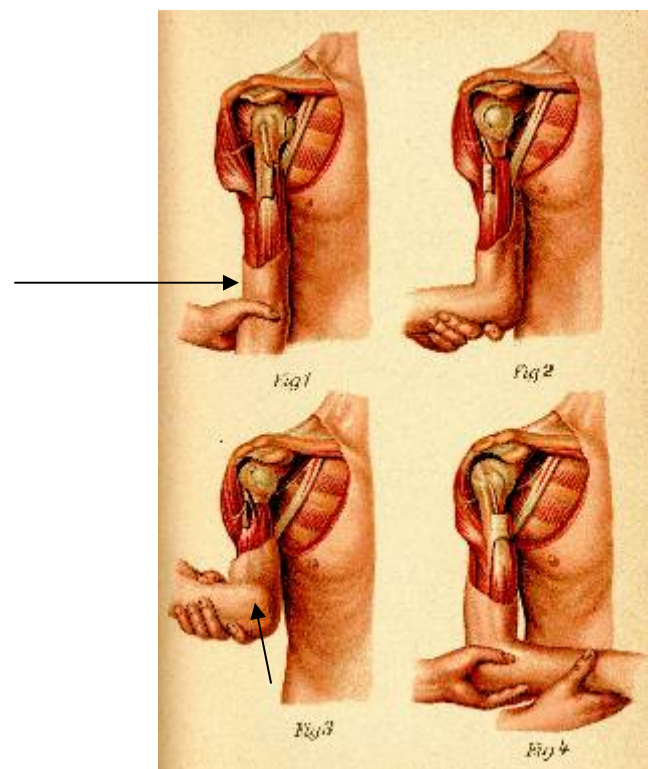
- Hole in canvas cot
- 10 pound sandbag hung on arm
- “After no greater than 6 minutes, reduction occurred due to muscle relaxation





Kocher's method (1870)

- Looked a lot like a wall painting on an Egyptian tomb from 1200 BC



Caution

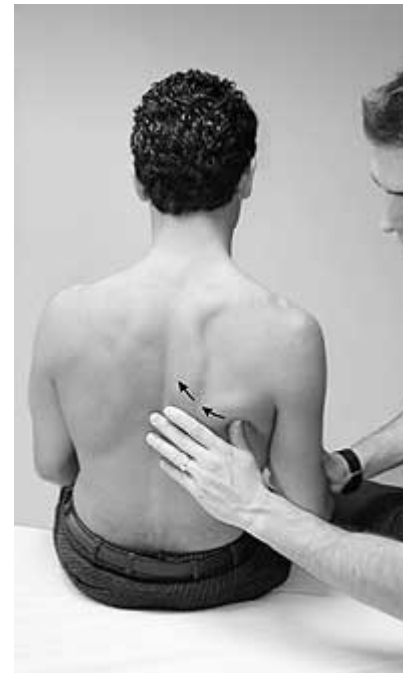
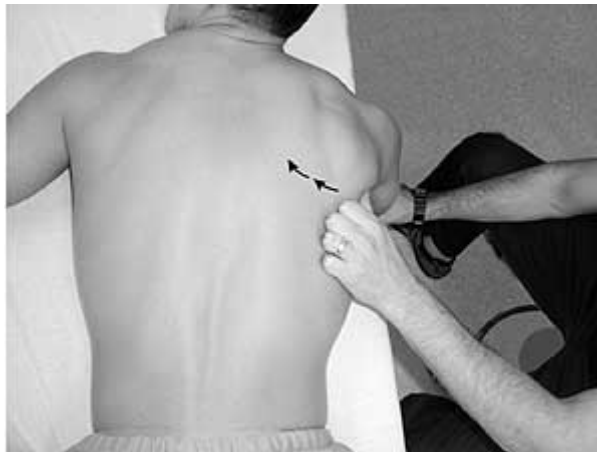
- May fracture humeral neck or shaft in elderly individuals



Scapular Manipulation

- Like Stimson's hanging arm technique, but with additional force on scapula
- Also attempted in seated and supine positions



These look fun too:

